

# Herniated discs

## *"Slipped discs"*

### WITH THE SHORT-LEGGED BREEDS



Photo: Wiegaarden/Jørgen Bak Rasmussen

The fact that short-legged dogs have an increased risk of having a disc herniation, compared to other breeds, is old news. Once, people thought it was due to "the long back", but today we know that the primary cause is a degeneration of the shock absorbing discs lying between the vertebrae. In fact, short-legged dogs do not have a long back either - they just have short legs.

**AUTHOR: HELLE FRIIS PROSCHOWSKY, DVM, PH.D., SPECIAL CONSULTANT, THE DANISH KENNEL CLUB (DKC)**

Originally published in the March 2019 issue of the Danish Kennel Club magazine (HUNDEN). Translated by Frøydís Hardeng and Ian Seath.

## BOX 1

# FGF4-gene



Cairn Terrier

West Highland White Terrier

French Bulldog



Beagle

Dachshund

Welsh Corgi

The background for the Dachshund's short legs is a special type of dwarfism. The scientific term is "chondodystrophic dwarfism" and it is also seen in e.g. Basset Hound, Welsh Corgi, Coton de Tulear, Shih Tzu and Lhasa Apso. The degree of dwarfism may vary, and breeds such as French Bulldog and Beagle are actually also "chondrodystrophic", although their legs are not quite as short. The cause of dwarfism is some extra copies of a gene called FGF4. The extra copies are a result of a special form of mutation, where parts of the DNA are copied and inserted elsewhere than originally (Box 1). Much suggests that the mutation is old - perhaps up to 4,000 years. Our ancestors were probably able to see that dogs with short legs could be useful. Therefore, they have maintained this trait through selective breeding. The FGF4 gene encodes a protein that helps regulate the growth of the long bones that are found especially in the legs. In the dogs that have extra copies of FGF4, more of this substance is produced. This causes growth to stop earlier than usual - and this results in shorter legs. Unfortunately, it has been found that other changes also occur, namely changes in the shock-absorbing discs lying between the vertebrae.

The dog's chromosomes are organized in pairs and the same genes are found on each chromosome. In this way, there are two copies of all genes.

All dog breeds have two copies of the FGF4 gene on chromosome 18.

The FGF4 gene has been copied and inserted to a new site twice in the dog's evolutionary history

- One time it has been inserted to a new position on chromosome 18
- The other time it was inserted on chromosome 12

The number and location of the copies are important for length of the legs as well as the risk of disc herniation.

Extra copies on chromosome 18:

- Short legs and low to moderate risk of disc herniation
- For example, Cairn Terrier and West Highland White Terrier

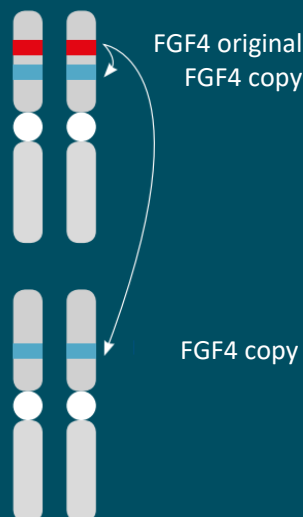
Extra copies on chromosome 12:

- Less reduction of leg length but increased risk of disc herniation
- For example, French Bulldog and Beagle

Extra copies on both chromosomes 18 and 12:

- Short legs and high risk of disc herniation
- For example, Dachshund and Welsh Corgi

### CHROMOSOME 18



### CHROMOSOME 12

A US DNA test has recently been published that examines the number of FGF4 copies on chromosome 12, which increases the risk of disc herniation. A validation of the test has unfortunately shown that it will not be useful as a breeding tool for Dachshunds in Denmark or the UK. It is possible that it may be useful in other breeds, but it should be examined separately.



## BOX 2

### Symptoms of disc herniation

- Pain that can either occur acutely or chronically
- Disturbed balance
- Reduced sensation in the hind legs
- Reduced reflexes in the hind legs
- Reduced control of urine and stools
- Paralysis in the hindquarters

- Always seek veterinarian assistance immediately if your dog shows symptoms of disc herniation
- In severe cases, time can be a decisive factor

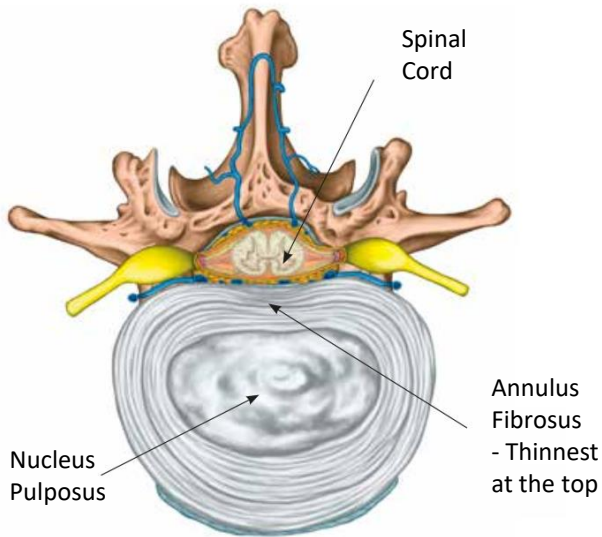
#### DIAGNOSIS

The diagnosis is made by a thorough clinical examination combined with contrast X-ray (myelography) or MRI

#### TREATMENT

Mild cases are treated with a combination of rest and medication

Severe cases are treated with surgery and subsequent rehabilitation



**Figure 1:** Cross section of a vertebrae. The disc consists of an external solid ring (Annulus Fibrosus) and a soft core (Nucleus pulposus). Annulus Fibrosus is thinnest just below the spinal cord and therefore it is often here it bursts.

#### Degeneration

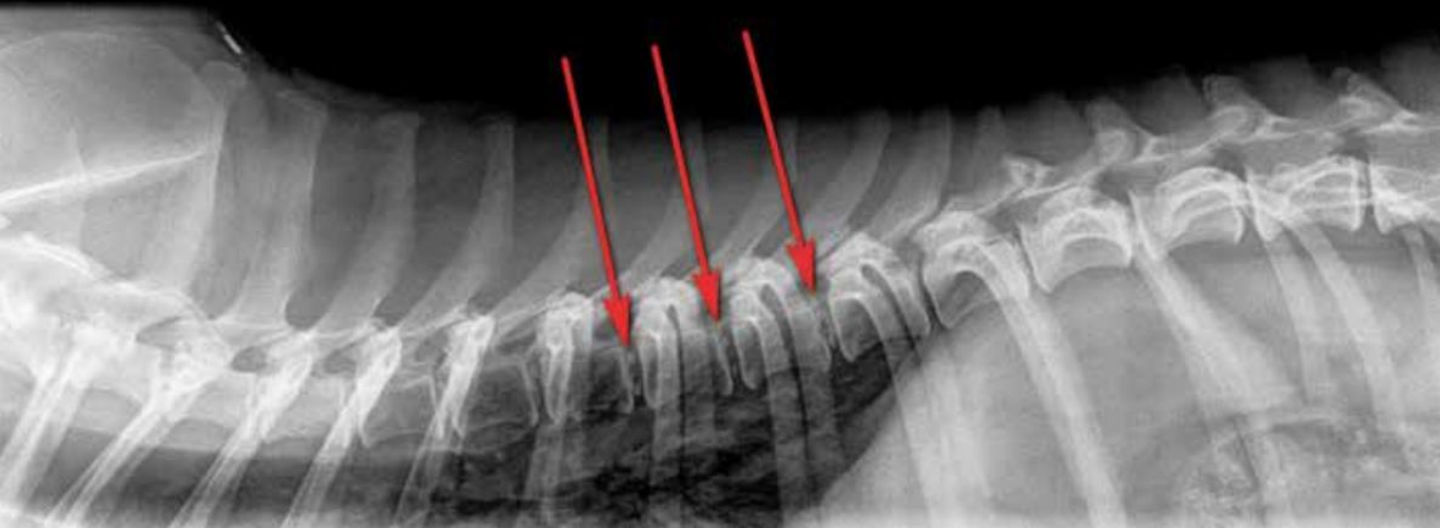Dogs' vertebrae can be divided into cervical vertebrae (7), thoracic vertebrae (13) and lumbar vertebrae (7). The sacrum is formed by three joined vertebrae and the tail typically consists of 20-23 tail vertebrae. The vertebrae are, among other things, present to help protect the spinal cord that runs inside. The shock-absorbing discs consist of an outer ring, called "Annulus Fibrosus" and a soft gelatinous core, called "Nucleus Pulposus" (Figure 1). In breeds without chondrodystrophic dwarfism, the nucleus contains some molecules that are capable of attracting water. They maintain a fine balance that ensures that the gel-like mass remains soft and elastic. However, in the short-legged breeds, the molecular composition of the nucleus changes, which means that the water content drops. The centre of the disc therefore becomes stiff and inelastic - just like plasticine, which becomes hard if it dries out. It is this change in the centre of the disc that is called "degeneration". The process begins during the dog's first year of life and means that there is a greater risk of the acute form of disc prolapse, which is called "Type 1". Here, the outer ring of the disc bursts and material from the core "shoots out". The outer ring of the disc is thinnest at the top - just below the spinal cord. If the herniation happens here, there may be damage to the spinal cord, which include lameness and paralysis. See the typical symptoms of disc herniation in Box 2.

”

Always seek veterinarian assistance immediately if your dog shows symptoms of disc herniation.



**Figure 2:** X-ray image of a dachshund's spine. The red arrows show examples of discs with visible calcification.



### **The degree of degeneration varies**

The centre of the discs degenerates in all dogs with this particular type of dwarfism and, over time, they can calcify and become visible on an X-ray. However, the degree of degeneration varies from dog to dog and by taking an X-ray and counting the number of calcified discs, one can get an impression of the degree of degeneration in the individual dog. In Dachshunds, several studies have shown that there is a clear correlation between the number of calcified discs and the risk of disc herniation (Box 3). However, this is not a complete 1: 1 relationship. Some dogs with many calcifications do not suffer disc herniation. Slightly simplified, it can be compared to the fact that there are also people who smoke heavily who do not get lung cancer. However, this does not change the fact that smoking is a risk factor for lung cancer and, likewise, many calcifications are a risk factor for disc herniation. Other factors seem to be able to protect chondrodystrophic dogs from disc herniations. For example, physically strong, slim and well-exercised dogs seem to have a lower risk of having a prolapse, even if they have many calcifications.

### **The number of calcifications**

The number of calcified discs is called the “K-number”, and it has proved to be highly heritable. In fact, the heritability is higher than for diseases such as, for example, HD (hip dysplasia) and ED (elbow joint dysplasia). As for HD and ED, the inheritance of disc herniation is described as "polygenic" or "multifactorial". This means that other genes are expected to be involved in the development of disc herniation, apart from FGF4. In addition, there are a number of environmental factors, some of which are known (e.g. as mentioned, physical exercise) and others not yet identified. As the K-number is heritable, it means that dogs with many calcifications often have offspring with many calcifications - and vice versa.

Therefore, you can use the K-number to select the best animals for breeding and to avoid the worst. As with HD, the Danish Kennel Club also calculates estimated breeding values (EBV or index) for calcifications in the back. Besides the dog's own back status, this calculation involves data from all X-rayed relatives. The estimated breeding value for each individual dog is related to the average of the breed, which is always set to 100. If you want to improve the breed's back health, you should use dogs with few calcifications and an estimated breeding value (index) above 100.

”

There is nothing illogical in the fact that a disc herniation can occur at another position than just where the degeneration is visible in the form of calcification.

### **The breeding program**

Denmark has been at the forefront when it comes to research into disc prolapse, and therefore the Danish Dachshund breeders have had the opportunity to X-ray their dogs' spines for almost 20 years. During this period of time, the screening programme has alternated between being voluntary and mandatory. This has not been optimal, and from April 1 2019 X-raying of both males and females will be mandatory (Box 4). Additionally, screening programmes have now been implemented in Norway, Sweden, Finland, Australia and UK as well. The Swedish images are scored in Norway and the UK images are scored in Finland. Based on the the number of calcified discs, the dogs are given a back status which can be Free (0 calcifications), Mild (1-2 calcifications), Moderate (3-4 calcifications) or Severe degree (5 or more calcifications) (Figure 2).

### BOX 3

## Calcification is a significant risk factor for the development of disc herniation



Veterinarian Sarah Beck examined the relationship between calcification and disc herniation for her thesis. She sent out a questionnaire to the owners of 61 dogs who had been back X-rayed in connection with a previous study by Vibeke Frøkjær Jensen. She asked whether the dogs had developed a herniated disc during their lifetime. The results are summarized in the following table:

Back status/K-number	Number of dogs with prolapse	Number of dogs without prolapse	Total
Free (K0)	1 (8 %)	11 (92 %)	12
Mild degree (K1–K2)	2 (14 %)	12 (86 %)	14
Moderate degree (K3–K4)	7 (44 %)	9 (56 %)	16
Severe degree (> K5)	12 (63 %)	7 (37 %)	19
Total	22 (36 %)	39 (64 %)	61

In 2014, Anu Lappalainen and her colleagues published a study of 193 back-X-rayed Finnish Dachshunds, all above the age of 10. This study also showed a correlation between the number of calcifications and the prevalence of disc herniation.

- Dachshunds with severe degree of calcifications had 18 times higher risk of disc herniation than dogs with back status "free"
- They concluded that back X-raying is an effective screening tool that can be used to reduce the incidence of disc herniation in Dachshunds

Finally, the veterinarians Tine Marx and Charlotte Mørck Andersen conducted a Masters thesis on back health in 2014:

- They contacted the owners of all Dachshunds that were X-rayed in 2004 - 2006 (153 dogs)
- A total of 117 owners returned with information about their dogs' status in relation to prolapse (response rate of 76%)
- They correlated the dogs' K-numbers and back index with the presence of disc herniations with the following result:
  - Dogs with five or more calcified discs had 11 times greater risk of disc herniation compared to dogs with fewer than five calcifications
  - Dogs with back indexes below 100 had a 15 times higher risk of disc herniation compared to dogs with back indexes above 100
- The prevalence of disc herniation in the three hair varieties was 16% (wire), 17% (long) and 21% (smooth) respectively.

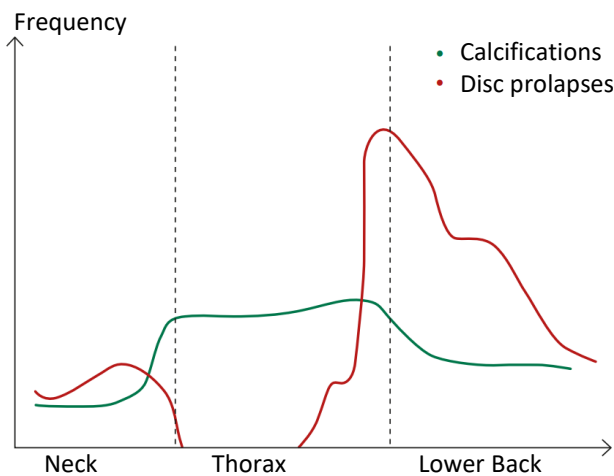


Although beagles do not have quite as short legs as Dachshunds, they still have the same form of dwarf growth.

Photo: Wiegaarden / Jørgen Bak Rasmussen



In order to get the most accurate picture of the dog's back status, and to be able to compare potential breeding animals, the X-rays must be taken between 2 and 4 years of age. Before the age of two, calcifications are not yet visible, and when the dog has passed 4 years, they can become more blurred. It is not because the degeneration disappears, but there may be some minor ruptures in the outer ring, which causes cells from the immune system to enter and "eat" the calcifications. The material from the Nucleus Pulposus can also slowly leak out of the small ruptures. This is sometimes called "silent prolapses" because they do not give rise to clinical symptoms in the same way as the acute prolapses. X-rays for evaluation of disc calcifications require experience and high quality X-ray equipment. Therefore, only a small group of authorised veterinarians offer this service in Denmark.



**Figure 3:** The two curves show how the incidence of calcifications (the green line) and disc prolapses (the red line) varies down through the spine. There is nothing illogical in the fact that a disc herniation can occur at another position than just where the degeneration is visible in the form of calcification. It is the anatomical conditions in the back that determine the distribution of calcification and prolapses.

Diagram modified by the author from an article by H. J. Hansen from 1952.

#### **Do prolapses always occur in calcified discs?**

No, they don't. The anatomy of the spine is important for the position of both calcifications and disc prolapses. The thoracic (chest) region is the area of the spine where there are fewer disc prolapses. This is due, among other things, to the fact that in this part of the back a ligament runs between the ribs, which protects against disc herniations in the upward direction towards the spinal cord. But the thoracic region is also an area where we see many calcifications. This may be because this part of the spine is not so flexible. The calcifications are not so easily formed in the discs that become "massaged" when the back moves. On the other hand, disc prolapses are most prevalent in the lumbar region - especially in the transition between the thoracic region and the lumbar region (Figure 3).



#### BOX 4

## New breeding rules for Dachshunds from April 1, 2019

### **Breeding Restriction:**

Both parents must be back X-rayed before breeding.

### **The following dogs can be used in breeding:**

Free: 0 calcifications

Mild degree: 1-2 calcifications

Moderate degree: 3-4 calcifications

### **Breeding Recommendation:**

The average of the parent animal's EBV (index) at the time of mating should be 100 or more.

The exact EBV formula for the individual varieties, rules for foreign dogs etc. can be found on DKC's database «dogweb» or on the Danish Dachshund Club's website (in Danish).

There are fewer calcifications here - again, probably due to increased mobility in this area of the back. This has occasionally caused some dog owners to doubt the relationship between calcification and prolapses. But there is nothing illogical in the fact that a disc herniation can occur at another position than just where the degeneration is visible in the form of calcification. All discs are degenerate to some extent – but the degeneration is not always visible on X-rays in the form of calcification. When operating on a dog for disc herniation, the disc material that the surgeon removes will often have the consistency of gritty toothpaste due to inorganic calcified material, even though the calcification was not visible on the X-ray.

### **Can you X-ray all breeds?**

At present, we only X-ray Dachshunds in Denmark. So far, no research has been done on the relationship between calcification and disc herniation in other breeds, but the expectation is that other chondrodystrophic breeds could be included in the current screening program. It would make good sense, because we know that there are problems with the spines of several other breeds. The Breed Club for Small Companion Dogs and the breed representative for Coton de Tulear have recently contacted DKC's health committee with intentions of initiating one or more back projects. One project will deal with the relationship between calcification and disc herniation and another will seek to evaluate if the DNA test mentioned in the box on the FGF4 gene is useful in a Danish setting. This is extremely positive, and hopefully it will be possible to expand the current breeding program with additional breeds.

## References

- Brown, Emily A et al. (2017): *FGF4 retrogene on CFA12 is responsible for chondrodystrophy and intervertebral disc disease in dogs*. PNAS, October 24, 2017, vol. 114, no. 43, pp. 11476-11481  
<https://www.pnas.org/content/114/43/11476> (Open Access)
- Hansen, H-J (1952): *A Pathologic-Anatomical Study on Disc Degeneration in Dog: With Special Reference to the So-Called Enchondrosis Intervertebralis*, Acta Orthopaedica Scandinavica, 23: Suppl. 11, pp. 1-130  
<https://www.tandfonline.com/doi/pdf/10.3109/ort.1952.23.suppl-11.01> (Open Access)
- Jensen, V. & Arnbjerg, J., 2001. *Development of Intervertebral Disk Calcification in the Dachshund: A Prospective Longitudinal Radiographic Study*. J. Am. Anim. Hosp. Assoc., 37(3), pp.274–282.  
<https://www.ncbi.nlm.nih.gov/pubmed/11361121>
- Jensen, V.F., Beck, S., Christensen, K.A. & Arnbjerg, J. (2008): *Quantification of the association between intervertebral disk calcification and disk herniation in Dachshunds*. Journal of the American Veterinary Medical Association, vol. 233, no. 7, pp.1090–1095.  
<https://www.ncbi.nlm.nih.gov/pubmed/18828719>
- Lappalainen et al. (2015) Estimate of heritability and genetic trend of intervertebral disc calcification in Dachshunds in Finland Acta Vet Scand, 57:78  
<https://actavetscand.biomedcentral.com/articles/10.1186/s13028-015-0170-7> (Open Access)
- Lappalainen, A. et al. (2014): *Intervertebral disc disease in Dachshunds radiographically screened for intervertebral disc calcifications*. Acta Veterinaria Scandinavica 56:89  
<https://www.ncbi.nlm.nih.gov/pmc/articles/PMC4285634/> (Open Access)
- Marx, T & Andersen, C. M. (2014): *Intervertebral Disc Herniation in Dachshunds; An Incidence Study and a Follow-up Study on spinal radiographic examination and the use of the number of intervertebral calcified discs and the breeding value*. Master Thesis from University of Copenhagen, Department of Veterinary and Animal Sciences, Section of Animal Genetics, Bioinformatics, and Breeding. Written in Danish with an English abstract.  
[http://www.dgk.dk/xdoc/332/diskusprolaps-hos-gravhunde\\_charlotte-moerck-andersen-tine-marx.pdf](http://www.dgk.dk/xdoc/332/diskusprolaps-hos-gravhunde_charlotte-moerck-andersen-tine-marx.pdf)
- Parker, H.G., et al. (2009): *An Expressed Fgf4 Retrogene Is Associated with Breed-Defining Chondrodysplasia in Domestic Dogs*. Science, 325(5943), pp.995–8.  
<https://www.ncbi.nlm.nih.gov/pubmed/19608863>

Further information: [www.dachshund-ivdd.uk](http://www.dachshund-ivdd.uk)